

available at www.sciencedirect.comjournal homepage: www.elsevier.com/locate/burns

Case report

Core warming of a burn patient during excision to prevent hypothermia

Joseph P. Corallo^{*}, Booker King, Louis R. Pizano, Nicholas Namias, Carl I. Schulman

DeWitt Daughtry Family Department of Surgery, University of Miami Miller School of Medicine, P.O. Box 016960 (D-40), Miami, FL 33101, United States

ARTICLE INFO

Article history:

Accepted 10 August 2007

Staged excision and grafting remains the mainstay of the surgical treatment of large burn injuries since Jackson and colleagues demonstrated a decreased mortality with excisions of 20% or less in 1960 [1]. The major factors limiting these excisions are blood loss and hypothermia. Despite these known limitations, little progress had been made in combating the hypothermia that comes with a large excision. The current re-warming strategies include: increasing ambient room temperature, infusing warm intravenous fluids, and using hot air technologies such as the Bair HuggerTM, but no single solution or combination of solutions has proven adequate [2]. Recently at our institution, a new intravascular warming catheter was used to perform a large burn excision with excellent results.

1. Case report

A 53-year-old male suffered a 70% total body surface area full thickness burn in an industrial incident. The patient was working on a machine used for pasteurization of orange juice using steam and he suffered burns from highly pressurized steam when the machine malfunctioned. Shortly after arrival and the institution of resuscitation and debridement, the patient required escharotomies to the bilateral forearms, hands, and lower extremities below the knees. Twenty-six

liters of fluid was given during the first 24 h and local wound care was with silvadene.

On hospital admission day 3 the patient was taken to the operating room for a staged excision of his burn wounds. Using a modified Seldinger technique a triple lumen Alsius IcyTM thermal regulation catheter was placed through the femoral vein into the inferior vena cava. The catheter was then connected to the thermal regulation device and active core warming of the patient was begun.

The operative plan was to excise as much of the burn eschar on the patient's extremities as possible, as limited by hypothermia and blood loss. A sterile tourniquet was used to control blood loss and was subsequently applied to each limb undergoing excision. As there was minimal variation in the patient's core body temperature, and blood loss was kept to a minimum, this enabled us to excise all four extremities approximately 30% total body surface area. Allograft was used to cover the wounds. The allograft was dressed with silver nitrate soaks. The patient tolerated the procedure well and was transported back to the intensive care unit.

Total operative time was 3 h and 9 min. The room was initially heated to 29.4 °C (85 °F), but was gradually cooled to 23.8 °C (75 °F) over 2 h. The patient maintained a core body temperature to within 1.2 °C of starting body temperature of 36.5 °C throughout the entire operative portion of the case.

^{*} Corresponding author.

E-mail address: jcorallo@med.miami.edu (J.P. Corallo).

0305-4179/\$34.00 © 2007 Elsevier Ltd and ISBI. All rights reserved.
doi:10.1016/j.burns.2007.08.012

2. Discussion

Hypothermia has several detrimental effects including impairment of the immune and stress responses, disruption of coagulation and platelet function, and dysfunction of normal neurologic and cardiac homeostasis [3]. The burn patient is predisposed to hypothermia because of the large amount of intravenous fluid used in resuscitation, escape of heat from burned skin and the exposure of the patient during transport and wound care [3]. General anesthesia blunts metabolic and neurologic responses to hypothermia further hampering the effort to keep the patient normothermic [4]. Hypothermia during tangential excision of burn increases blood loss and the risk of morbidity and mortality. The risks of adverse outcomes are magnified when 20% or more of burned skin is excised [1]. Warden et al. recommended two staged excisions for cases exceeding 2 h. This was done in attempt to limit blood loss and prevent hypothermia [5].

There are several devices currently utilized to maintain normothermia in the operating room. The Bair Hugger™ uses warmed air forced through a hose into an inflatable blanket. Other devices warm intravenous fluids (Standard Ranger, Hotline, Fluido, and Level I) but none of these devices were consistently able to keep the patient's core temperature $>36^{\circ}\text{C}$ in a recent study [2]. Infusing hot saline ($55\text{--}60^{\circ}\text{C}$) through central venous catheters during excision and grafting of burn wounds was found to be safe but temperature regulation was limited by the volume of heated crystalloid infused during the surgeries [6].

The CoolGard 3000™ (Alsius) system is a new temperature regulation device. The catheter (Fig. 1) is inserted into the central venous system via either the femoral and subclavian routes (using the modified Seldinger technique). The system circulates cool or warm sterile saline through multiple balloons attached to the catheter's shaft. The patient is cooled or warmed as blood passes around the catheter and enters the central circulation. The main console and warming unit constantly senses the patient's core temperature from any

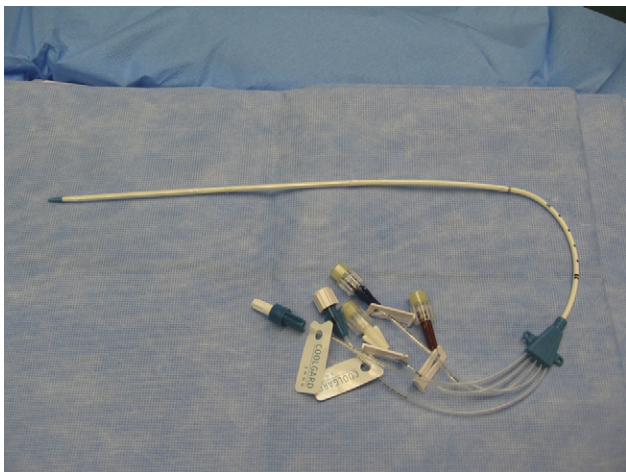


Fig. 1 – The thermal management catheter is a standard triple lumen catheter with two additional parts (light blue) that form a continuously running closed loop of warmed sterile saline that fills three balloons around the catheter body.

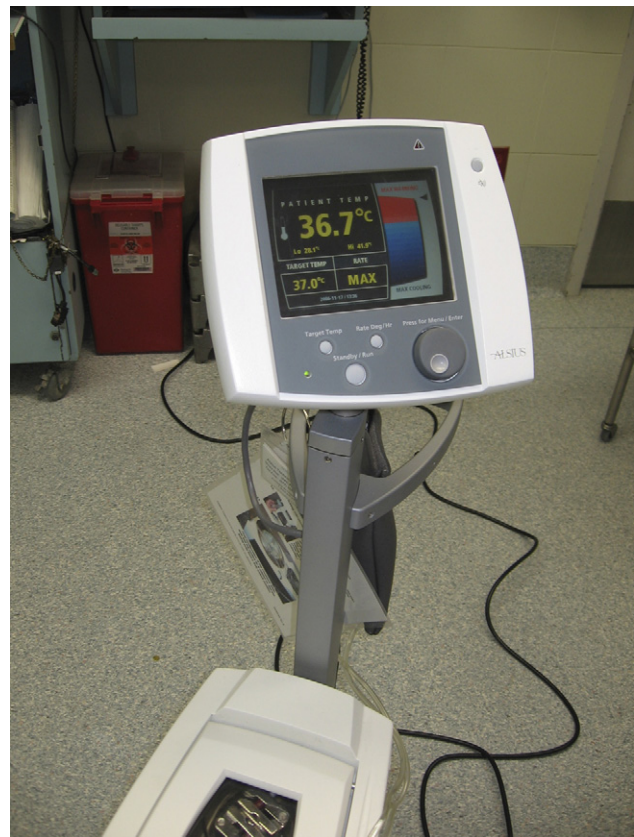

Fig. 2 – User interface for thermal management system.

standard temperature probe. The system adjusts the temperature of the fluid in the balloons until the preset target core temperature is achieved (Fig. 2) [7]. The catheter has been used mostly to induce hypothermia in patients with intracranial hemorrhage, ischemic stroke, head injury and spinal cord injury [8]. Hypothermia has been shown to be neuroprotective in some studies and it has been utilized in the perioperative management of patients after brain and spinal cord surgery [9,10]. There are sporadic reports of using hypothermia to management patients after resuscitation from major cardiac events as well [11]. The period of hypothermia ranges from several hours to 3 days in most studies and the patients are slowly re-warmed to a target temperature (usually 37°C) [12,13].

The use of an intravenous warming catheter is a novel approach to maintaining normothermia during burn surgery and this may be more effective than traditional methods. In this case the patient had tangential excision of approximately 30% total body surface area burn. The patient's temperature was 36.5°C before the start of the operation. A temperature above 36°C was maintained throughout most of the case. The initial room temperature was set to 29.4°C (85°F) and gradually lowered to 23.8°C (75°F) with only minute changes in the patient's core temperature. It is our practice to abort surgery in burn patients once their core body temperature declines below 35.5°C . Based on previous experience we would not have been able to excise and graft as much of this patient's burn wound because his temperature would have rapidly fallen below the threshold temperature.

In summary, intraoperative hypothermia limits the amount of burn wound that can be excised and grafted. Traditional devices can maintain core body temperature but are inconsistent and therefore have variable efficacy. We report the use of an intravenous catheter for maintaining normothermia during extensive excision and grafting of a large burn wound. We have found that this system reliably and consistently maintained the target core body temperature throughout the operation. While this system appears to be safe and effective, additional studies are needed to completely assess its safety and efficacy in burn patients.

Conflict of interest statement

The authors have no potential conflicts of interest to disclose regarding this case report.

REFERENCES

- [1] Jackson D, Topley E, Carson J, Lowbury E. Primary excision and grafting of large burns. *Ann Surg* 1960;152:167–89.
- [2] Turner M, Hodzovic I, Mapleson WW. Simulated clinical evaluation of four warming devices. *Anaesthesia* 2006;61:571–5.
- [3] Luna GK, Maier RV, Pavlin EG, Anardi D, Compass MK, Oreskovich MR. Incidence and effect of hypothermia in seriously injured patients. *J Trauma* 1987;27(9): 1014–8.
- [4] Shiozaki T, Kishikawa M, Hiraide A, Shimazu T, Sugimoto H, Yoshioka T, et al. Recovery from postoperative hypothermia predicts survival in extensively burned patients. *Am J Surg* 1993 Mar;165:326–30.
- [5] Warden GD, Saffle JR, Kravitz M. A two stage technique for excision and grafting of burn wounds. *J Trauma* 1982;22(2):98–103.
- [6] Fildes J, Sheaff C, Barrett T. Very hot intravenous fluid in the treatment of hypothermia. *J Trauma* 1993;35(5 (November)):683–7.
- [7] Polderman KH, Callaghan J. Equipment review: cooling catheters to induce therapeutic hypothermia? *Crit Care* 2006;10(6 (November)):234.
- [8] Diringner MN. Treatment of fever in the neurologic intensive care unit with a catheter based heat exchange system. *Crit Care Med* 2004;32(2):1–6.
- [9] Ferdinande P. What works in severe head injury? *Curr Opin Anaesthesiol* 2001;14(2 (April)):151–5.
- [10] Fountas KN, Kapasalki EZ, Johnston KW, Smisson 3rd HF, Vogel RL, Robinson Jr JS. Postoperative lumbar discectomy pain. Minimalization by irrigation and cooling. *Spine* 1999;24(18 (September)):1958–60.
- [11] Al Senani FM, Graffagnino C, Grotta JC, Saiki R, Wood D, Chung W, et al. A prospective multicenter pilot study to evaluate the feasibility and safety of using the CoolGard system and Icy catheter following cardiac arrest. *Resuscitation* 2004;62(2 (August)):143–50.
- [12] Aiyagri V, Diringner MN. CoolGard/CoolLine catheter system. *Neurocrit Care* 2004;1(2):209–11.
- [13] Schmutzhard E, Engelhardt K, Beer R, Brossner G, Pfausler B, Spiss H, et al. Safety and efficacy of a novel intravascular cooling device to control body temperature in neurologic intensive care patients: a pilot study. *Crit Care Med* 2002;30(11 (November)):2481–8.